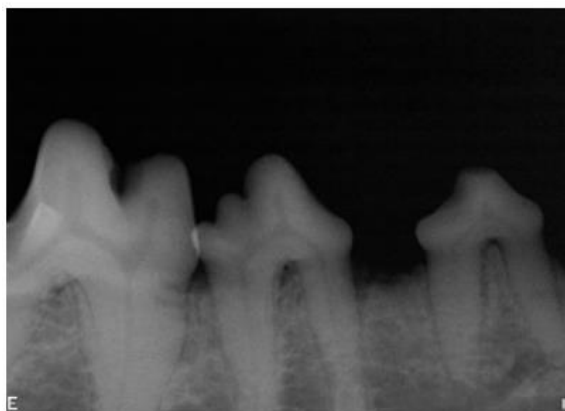
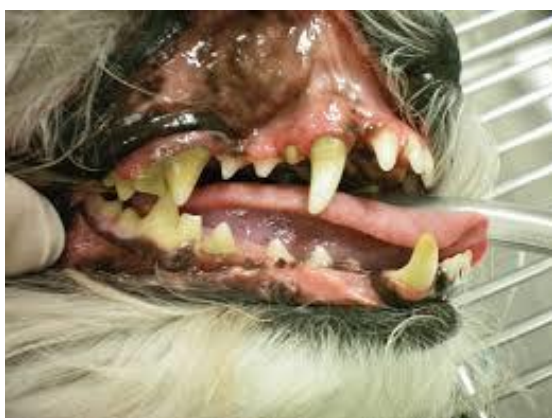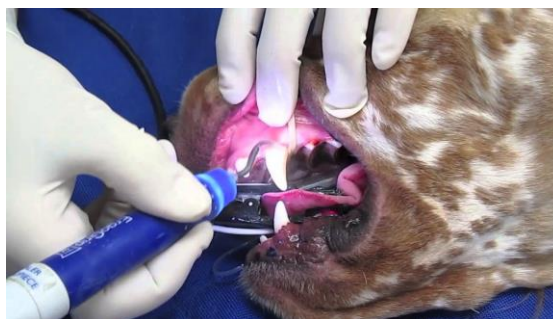

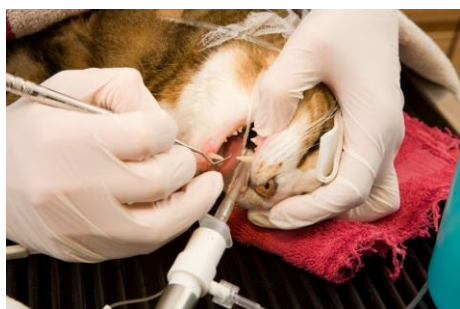
Grade 2 Periodontal disease



Grade 2 dental disease can be described as mild to moderate tartar built up on the teeth. You'll notice the gumline will be even more inflamed and sore from the infection that is building up. At this point, daily brushing will not remove the tartar and infection that has started. The only way to remove the buildup and infection under the gum line is by a dental cleaning with your pet under anesthesia.



All teeth are x-rayed in order to see any possible bone or gum loss caused by the infection. All teeth will then be scaled and polished to remove existing tartar and prevent tartar build up from happening quicker. Generally, by stage 2 there is only 0-25% of bone loss happening around the teeth. By taking the x-rays, we are able to have a clear view of healthy or diseased, fractured etc teeth and remove any if needed. *Most* pets will not need extractions during stage 2.

Don't let your pet's mouth get worse! Get your pet scheduled for a dental cleaning today!

